



COMMISSIONED PAPER (D)

Prevalence, grading and genetics of hemivertebrae in dogs

*E. Schlensker*¹, O. Distl¹*

SUMMARY

Hemivertebrae are the most frequent vertebral malformations in dogs and particularly common in chondrodystrophic dog breeds like the French bulldog, English bulldog, Pug and Boston terrier. Clinical signs caused by hemivertebrae are pelvic limb ataxia and paresis, loss of reflexes, kyphosis, lordosis and scoliosis, incontinence, atrophy and atony of the pelvic limbs due to a compression of the spinal cord. Hemivertebrae can be unilateral or bilateral. The standard diagnostic routine relies on ventrodorsal and lateral x-rays or even computer tomography. A few breeding associations request a mandatory x-ray examination for future breeding dogs to exclude individuals with a high number of hemivertebrae and/or hemivertebra at critical localisations in the thoracic spine or highly malformed vertebrae. Heritability estimates in French bulldogs indicate that breeding progress can be made using selective breeding and predicting breeding values for future breeding animals.

key words: hemivertebra, screening, heritability, dog

This paper was commissioned by FECAVA for the special issue of EJCAP, Genetic/Hereditary Disease and Breeding.

Introduction

Hemivertebrae, also called wedge-shaped vertebrae, are among the most frequent vertebral malformations in the dog^[1]. This condition is assumed to be highly heritable^[2]. The first reports in dogs date back for more than 100 years. Hemivertebrae are common in chondrodystrophic dog breeds, but may also be infrequently seen in other breeds like Pomeranians^[3] and Dobermann pinschers^[4]. Neurological signs accompanying hemivertebrae due to a

compression of the spinal cord become manifest in 3 - 4 month old dogs. Pelvic limb ataxia and paresis, loss of reflexes, kyphosis, lordosis and scoliosis, incontinence and atrophy and atony of the pelvic limbs are seen in affected dogs^[5, 6].

The objectives of this article are to review the prevalences and possible hereditary influences on hemivertebrae in dogs. The grading schemes used in dog breeding programs are discussed and a genetic analysis on hemivertebrae in French bulldogs is presented. Herein, we could show a considerable genetic variation underlying this condition in French bulldogs and this may stimulate efforts to implement breeding programmes.

1 Institute for Animal Breeding and Genetics, University of Veterinary Medicine, Foundation, Bünteweg 17p 30559 Hannover, Germany
E-mail: Eva.Schlensker@yahoo.de

*Corresponding author Eva Schlensker, Weyerstraße 114 D-50676 Köln

Pathogenesis

Vertebrae derive from sclerotomes which surround the neural tube and the notochord and form the primordial vertebrae in the early embryonic development. Vertebrae have three ossification centres. At birth, ossification of these cartilaginous centres is only partial. Ossification of the vertebrae is completed by 7-9 months of age^[7]. Hemivertebrae in dogs are caused by an asymmetrical development or a failure in fusion of two ossification centres^[5]. There exist two forms of hemivertebrae: unilateral and bilateral.

Unilateral hemivertebrae occur when the right and the left half of the vertebrae develop asymmetrically^[3, 6, 4, 8]. These vertebrae are wedge shaped with the base orientated dorsally, ventrally or laterally^[9, 6].

Bilateral vertebrae are caused by a non-union of the right and left halves of the vertebrae body. This malformation is termed butterfly vertebrae^[5, 3, 4, 8]. Hemivertebrae may be single or multiple. The bilateral hemivertebrae often do not evoke clinical signs^[5, 6, 2, 8].

Diagnosis, Screening and Grading

Some breeding associations have implemented systematic breeding programmes based on phenotypic records of x-rays of the vertebral column. Diagnosis and grading of hemivertebrae are usually based on a radiological examination with ventrodorsal and lateral x-rays of the vertebral column (Fig. 1, Fig2)^[8]. Age at examination should be between 10^[10, 11] and 12 months^[13, 13]. There

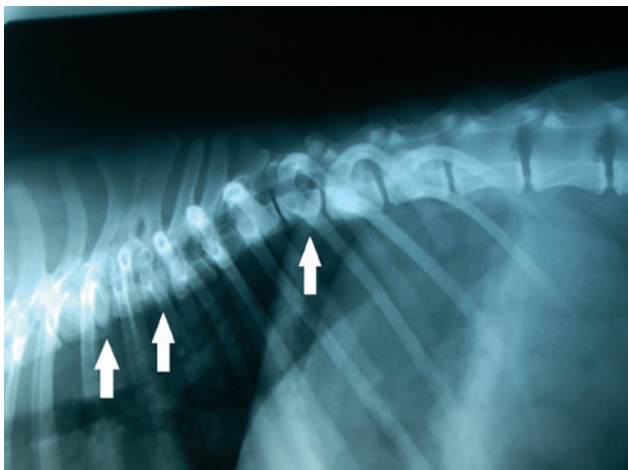


Fig. 1: X-ray from a French bulldog of the German Club of French Bulldogs with Hemivertebrae in the thoracic spine (white arrow)

is no agreement whether the dogs for the radiographic examination have to be sedated or anaesthetized. Dog breeding associations tend to suppose that radiography may be performed without anaesthesia. However, anaesthetists feel more secure having small brachycephalic dogs with possible upper airway problems anaesthetized, rather than just sedated^[12, 13].

There are two standard positions for the required radiography. The dog has to be placed in a lateral position, because of the lack of consequences of bilateral hemivertebrae^[10, 11] or in a lateral and ventrodorsal position^[14, 12]. The x-rays have to show at least T1 (thoracic vertebrae 1) to L7 (lumbar vertebrae 7) centred on T8-L1^[12, 13] or on the junction between thoracic and lumbar spine. Some breeding associations require x-rays from the whole thoracic and lumbar spine and the beginning of the caudal spine or even the whole spine^[14].

The extent of the dorsal dislocation towards the posterior of the respective vertebrae, and the degree of the spinal cord compression can be detected with the help of a lateral myelogram^[4] or a magnetic resonance and computed tomography^[8].

Classification of hemivertebrae for preventive health examinations is done by one panelist for a dog breeding association. Grading regards number, localization and severity of the malformation of all single hemivertebrae^[10, 11, 14, 12, 13]. Some panelists also record the number of the caudal vertebrae^[10, 11].

In some German dog breeding associations this classification is based on hemivertebrae number and location, with grade 1 = no hemivertebrae, grade 2 = 1

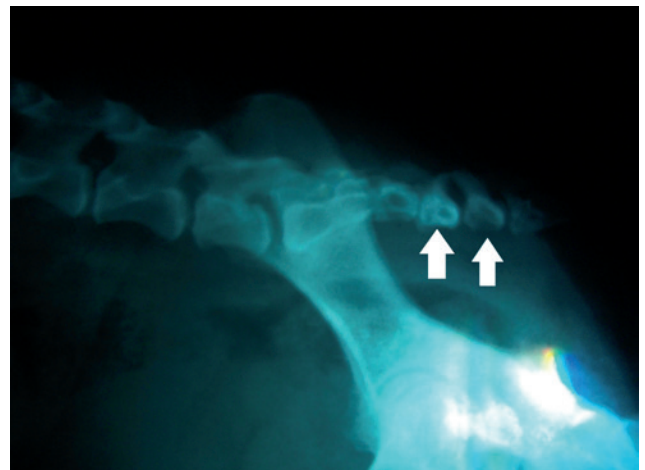


Fig. 2: X-ray from a French bulldog of the German Club of French bulldogs with a screw tail due to a Hemivertebrae (white arrow)

- 3 hemivertebrae, grade 3 = 4 - 6 hemivertebrae, grade 4 = > 6 hemivertebrae, grade 5 = hemivertebrae between thoracic and lumbar spine. Animals with grades 4 and/or 5 are excluded from breeding^[10, 11]. Other dog breeding associations use a scheme with following scores: any hemivertebrae at T1 - T7 = score 1, any hemivertebrae at T8 - T11 = score 2, any hemivertebrae at T12 - T13 = score 3. Animals with score > 1 are excluded from breeding^[14].

Because the angle of the vertebral column – rather than the number of hemivertebrae – is decisive for clinical signs^[15], a four-point-measurement of hemivertebrae (after Felsenberg and Kalender) was introduced into the classification system used by German dog breeding associations. Measurements record the dorsal (distance from A to B indicating the leading and rear edge of the dorsal surface of the vertebral body) and ventral (distance from C to D indicating the leading and rear edge of the ventral surface of the vertebral body) length of each hemivertebra (Fig. 3). The differences between the dorsal and ventral vertebral body length measurements are scored according to Armbecht^[18] in 5 classes (grade 0 = vertebral body lengths are identical, grade 1 = < 20% difference among dorsal and ventral vertebral body lengths, grade 2 = 20 - 40% difference, grade 3 = 40 - 60% difference, grade 4 = > 60% difference) (Tab. 1).

Prevalence and Genetics

Hemivertebrae are common in chondrodystrophic breeds like French and English bulldog, Pug, Boston terrier or

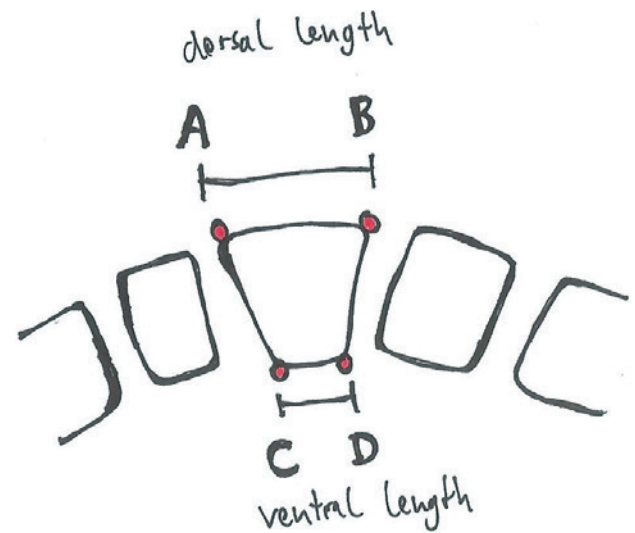


Fig. 3: Measurement of affected vertebrae with the Four-Point-System. Measuring the dorsal (d) and ventral (v) level (Felsenberg-Kalender)

Pekingese^[5, 16, 3, 9, 1, 7, 2, 8]. These dogs originate from screw tailed breeds as a breed characteristic due to caudal hemivertebrae^[3, 17, 6, 8]. Coccygeal hemivertebrae have been favoured in selective breeding as a desirable phenotype in many brachycephalic breeds. Selection for screwed tails is believed to enhance the risk for hemivertebrae in the thoracic and lumbar spine^[17, 9]. The occurrence of hemivertebrae is not restricted to chondrodystrophic breeds but is also infrequently seen in other breeds like Pomeranian dog^[3] and Dobermann pinschers^[4] and mongrels (Tab. 2).

The male to female ratio does not suggest any sex specific influences^[3]. A study in Italy about hemivertebrae in English bulldogs reported an incidence of 97.3%^[19]

Tab. 1: The four-point-measurement of hemivertebrae according to Felsenberg and Kalender was introduced into the classification system used by German dog breeding associations. A graduation from degree 0 to degree 4 is developed by measuring the dorsal (distance from A to B indicating the leading and rear edge of the dorsal surface of the vertebral body) and ventral (distance from C to D indicating the leading and rear edge of the ventral surface of the vertebral body) length of each hemivertebra

Grade	Grading system according to German dog breeding associations	Grade	Grading system according to Felsenberg and Kalender
1	No Hemivertebrae	0	vertebral body lengths are identical
2	1-3 Hemivertebrae	1	< 20% difference between dorsal and ventral vertebral body lengths
3	4-6 Hemivertebrae	2	20 - 40% difference between dorsal and ventral vertebral body lengths
4	More than 6 Hemivertebrae	3	40 - 60% difference between dorsal and ventral vertebral body lengths
5	Hemivertebrae between thoracic and lumbar spine	4	> 60% difference between dorsal and ventral vertebral body lengths

Tab. 2: Occurrence of Hemivertebrae in different dog breeds

Breed	Number of dogs examined	Affected dogs	References
German Shorthaired Pointer	29	10	Kramer et al., 1982
French bulldog	95	83	Grebe, 1984
English bulldog	38	36	Grebe, 1984; Volta et al., 2005
Yorkshire terrier	1	1	Done et al., 1975
Pug	10	10	Jeffery et al., 2007
Fox terrier	1	1	Kirberger, 1989
Pekingese	6	6	Done et al., 1975; Ruberte et al., 1995
Westhighland white terrier	1	1	Done et al., 1975
Pomeranian	1	1	Done et al., 1975
Dobermann pinscher	1	1	Thilagar et al., 1998
Crossbreed	4	4	Besalti et al., 2005

In our current study, 105 French bulldogs were examined using lateral radiographs of the vertebral column. The dogs were born between 1994 and 2011. The pedigree file included 809 animals up to five generations. Prevalence of hemivertebrae was 86.7% of which 44% of the affected dogs were males. There was no significant sex difference for the number and grade of hemivertebrae. The highest frequency of hemivertebrae was in T6 - T12. This distribution of hemivertebrae is in agreement with the report on English bulldogs from Italy^[19]. The mean inbreeding and relationship coefficients were slightly higher for the affected French bull dogs compared to unaffected dogs.

diagnosed as affected by hemivertebrae. There are affected and unaffected dogs in one litter as well as a litter with only affected members and one unaffected parent. Hemivertebrae are not seen in every generation, so a recessive trait is more likely. An X-linked inheritance can be ruled out, because affected dams have unaffected sons.

A linear animal model was employed to estimate heritabilities for the number and grade of hemivertebrae

Tab. 3: Heritability estimates for the appearance of number of Hemivertebrae and for the grade of Hemivertebrae (total number of animals: 694, base animals: 278)

Hemivertebrae	Heritability	Standard deviation
Grade	0.24	0.13
Number	0.64	0.12

Figure 4 shows the pedigree of one French bulldog family including 102 dogs. Out of these, 52 animals had been examined for hemivertebrae and 43 animals had been

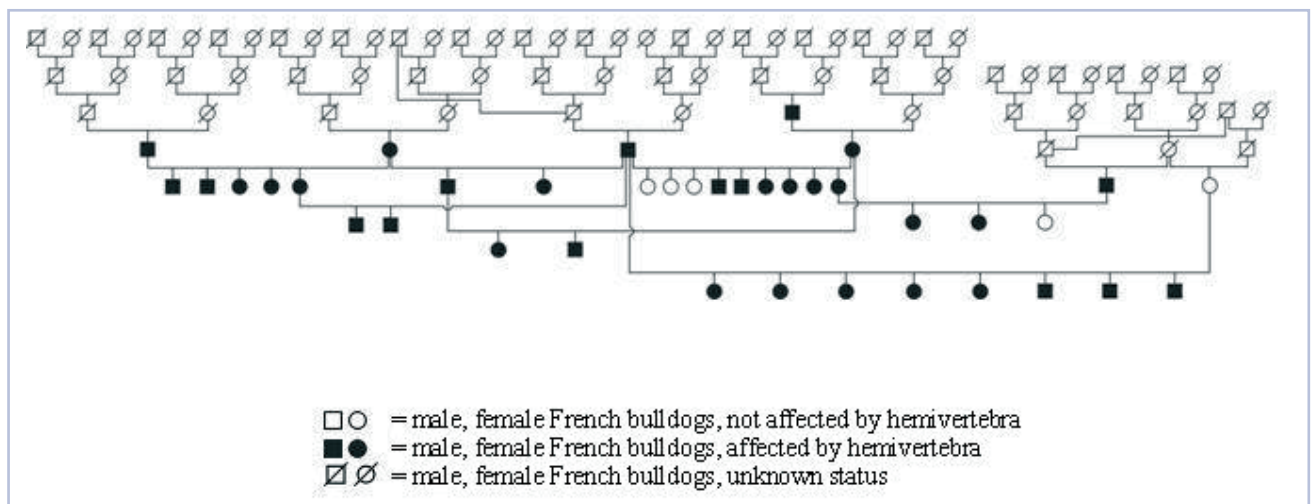


Fig. 4: A pedigree from one French bulldog family, including 102 dogs

using VCE, version 5.1.2. Heritability estimates were at 0.64 ± 0.12 for the number of hemivertebrae and at 0.24 ± 0.13 for the grade of hemivertebrae, respectively (Tab. 3). In English bulldogs and Yorkshire terriers a familial correlation has been reported^[3]. An autosomal recessive trait for hemivertebrae in German short-haired Pointer had been assumed^[20, 17].

Conclusions

Very high prevalences of hemivertebrae were shown for French and English bulldogs and further chondrodystrophic dog breeds. In most cases, the animals do not show any clinical signs, but hemivertebrae may evoke a compression of the spinal cord in the long term and this can therefore be the reason for neurological signs. Breeding programmes to reduce the prevalences of hemivertebrae should be effective due to the large genetic variation in the number and localization of hemivertebrae and their degree of malformation. However, there is lack of information on the degree of spinal cord compression in dogs affected by hemivertebrae and clinical signs in older dogs resulting from hemivertebrae.

Acknowledgement

The authors express their gratitude to the German Club of French Bulldogs (Deutscher Klub für Französische Bulldoggen, DKFB) and the German Dog Sport Union (Deutsche Hundesport Union, DHSU) for providing radiographs and pedigree data.

References

- [1] Ruberte J, Anor S, Carretero A, Vilafranca M, Navarro M, Mascort J, Pumarola M. Malformations of the vertebral bodies and the ribs associated to spinal dysraphism without spina bifida in a Pekingese dog. *J Am Vet Med Asso.* 1995; 42: 307-313
- [2] Besalti O, Ozak A, Eminaga P, Eminaga S. Nasca classification of hemivertebrae in five dogs. *I Vet J.* 2005; 8: 688-690
- [3] Done SH, Drew RA, Robins GM, Lane JG. Hemivertebrae in a dog: clinical and pathological observations. *Vet Rec.* 1975; 96: 313-317
- [4] Thilagar S, Gopal MS, Dewan Muthu Mohammed MS. Hemivertebrae in a dog. *Ind Vet J.* 1998; 75: 163-164
- [5] Grenn HH, Lindo DE. Hemivertebrae with severe kypho-scoliosis and accompanying deformities in a dog. *Can Vet J.* 1969; 10: 214-216
- [6] Bailey CS, Morgan JP. Congenital spinal malformations. *Small Anim Pract.* 1992; 22: 985-1015
- [7] Wright JA. Congenital and developmental abnormalities of the vertebrae. *J Small Anim Pract.* 1979; 20: 625-634
- [8] Jeffrey N, Smith PM, Talbot CE. Imaging findings and surgical treatment of hemivertebrae in three dogs. *J Am Vet Med Assoc.* 2007; 230: 532-536
- [9] Grebe J. The French Bullytin. 1984; 3: 11-15
- [10] Deutscher Klub für Französische Bulldoggen e.V.: Ergänzungs-Zuchtordnung [homepage on the Internet]. c2009 [updated 2009 Jan 12; cited 2013 Aug 14]. Available from <http://www.dkfb.de/doks/zo.pdf>
- [11] Deutsche Hunde Sport-Union e.V.: Verbandszuchtordnung [homepage on the Internet]. c2008 [updated 2008 Apr 29; cited 2013 Aug 14]. Available from http://www.dhsu.de/DHSU_Zuchtordnung__April_2008.pdf
- [12] The Pug Dog Welfare & Rescue Association: Hemivertebrae Screening – Procedure [homepage on the Internet]. c2013 [updated 2009; cited 2013 Aug 14]. Available from <http://pugwelfare-rescue.org.uk/hemivertebrae-screening-scheme/hemivertebrae-screening-procedure-2/>
- [13] White D. Screening for hemivertebrae in pugs. *Vet Rec.* 2013; 1: 24
- [14] French Bulldog Club of New South Wales : Health screening [homepage on the Internet]. c2013 [updated 2013; cited 2013 Aug 14]. Available from http://www.frenchbulldogclubnsw.asn.au/health_screening.html
- [15] Moissonnier P, Gossot P, Scotti S. Thoracic kyphosis associated with hemivertebrae. *Vet Surg.* 2011; 40: 1029-1032
- [16] Drew RA. Possible association between abnormal vertebral development and neonatal mortality in bulldogs. *Vet Rec.* 1974; 94: 480-481
- [17] Kramer JW, Schiffer SP, Sande RD, Whitener EK. Characterization of heritable thoracic hemivertebrae of the German shorthaired pointer. *J Am Vet Med Assoc.* 1982; 181: 814-815
- [18] Armbrecht G. Inzidenz der vertebraelen osteoporotischen Fraktur in Deutschland [dissertation] Fachbereich Vet Med: Freie Universität Berlin; 2001
- [19] Volta A, Morgan JP, Gnudi G, Bonazzi M, Gazzola M, Zanichelli S, De Risio L, Bertoni G. Clinical-radiological study of the vertebral abnormalities in the English bulldog. *European Association of Veterinary Diagnostic Imaging - EAVDI- 12th Annual Conference, Naples 2005, 31*
- [20] Breur GJ, Lambrechts NE, Todhunter RJ. The genetics of canine orthopaedic traits. In: Ostrander E, Ruvinsky A, editors. *The Genetics of the Dog*, 2nd edition, New York: CABI Publishing, 2012; p. 138.